

# Research methodology – University of Turku, Finland



- Prospective, controlled cohort study started in 1998
- Treatment group:
  - 167 children
  - Treatment with eruption guidance appliance only
- Control group:
  - 104 children
  - No treatment

Keski-Nisula K; Keski-Nisula L; Salo H; Voipio K, Varrela J. Dentofacial Changes after Orthodontic Intervention with Eruption Guidance in the Early Mixed Dentition. *Angle Orthod* 2008;78:324-331

Keski-Nisula K, Hernesniemi R, Heiskanen M, Keski-Nisula L, Varrela J. Orthodontic intervention in the early mixed dentition: A prospective, controlled study on the effects of the eruption guidance appliance. *Am J Orthod Dentofacial Orthop* 2008;133:254-260

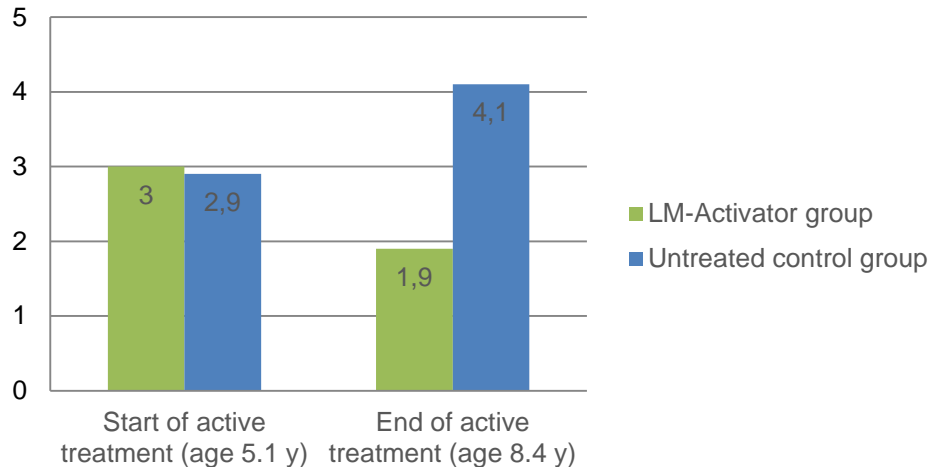
Varrela J. Class II Correction in the Early Mixed Dentition. American Association of Orthodontists, Annual Meeting, May 13.-17. 2011, Chicago, IL, USA

Varrela J. Effectiveness of the eruption guidance in early orthodontic treatment. World Federation of Orthodontists 7th International Orthodontic Congress, Feb 6.-9. 2010, Sydney, Australia

# Research results – University of Turku, Finland



## Overjet (mm)

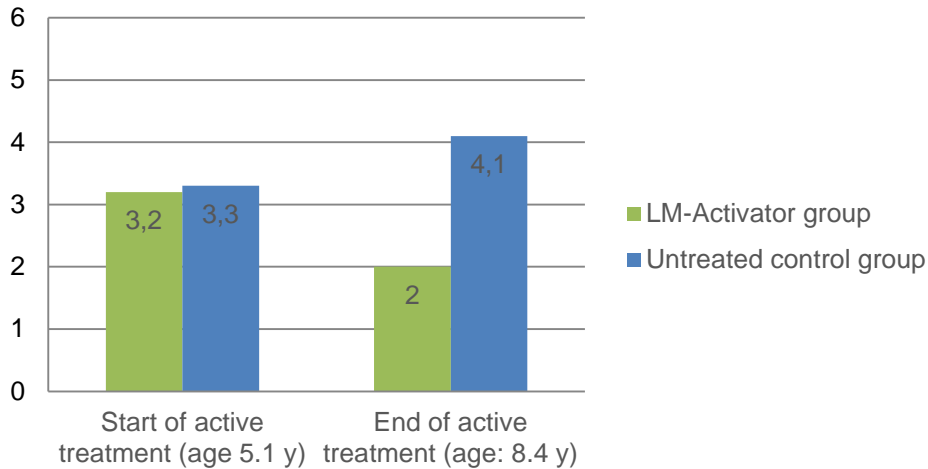


Keski-Nisula K; Keski-Nisula L; Salo H; Voipio K, Varrela J. Dentofacial Changes after Orthodontic Intervention with Eruption Guidance in the Early Mixed Dentition. Angle Orthod 2008;78:324-331.

# Research results – University of Turku, Finland




## Overbite (mm)

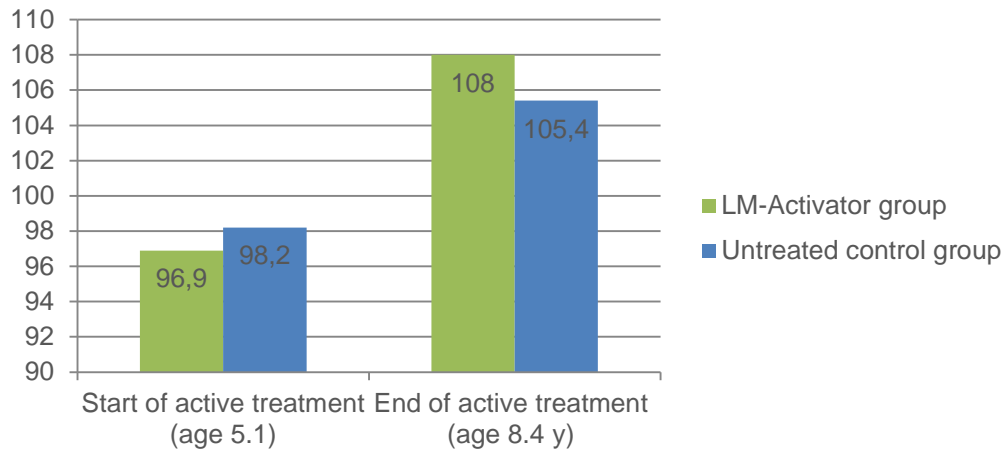


Keski-Nisula K; Keski-Nisula L; Salo H; Voipio K, Varrela J. Dentofacial Changes after Orthodontic Intervention with Eruption Guidance in the Early Mixed Dentition. Angle Orthod 2008;78:324-331.

# Research results – University of Turku, Finland



## Mandibular length/Condylion-Gnathion



Keski-Nisula K; Keski-Nisula L; Salo H; Voipio K, Varrela J. Dentofacial Changes after Orthodontic Intervention with Eruption Guidance in the Early Mixed Dentition. Angle Orthod 2008;78:324-331.

# Research results – University of Turku, Finland



## Incisor contact

	Treatment group		Control group	
	Start of active treatment (age: 5.1y)	End of active treatment (age: 8.4y)	Start of active treatment (age: 5.1y)	End of active treatment (age: 8.4y)
Tooth-to-tooth	18%	<b>99%</b>	22%	24%
Open bite / Gingival deep bite	82%	1%	78%	76%

Keski-Nisula K, Hernesniemi R, Heiskanen M, Keski-Nisula L, Varrela J. Orthodontic intervention in the early mixed dentition: A prospective, controlled study on the effects of the eruption guidance appliance. Am J Orthod Dentofacial Orthop 2008;133:254-260

# Research results – University of Turku, Finland



## Crowding

	Treatment group		Control group	
	Start of active treatment (age: 5.1y)	End of active treatment (age: 8.4y)	Start of active treatment (age: 5.1y)	End of active treatment (age: 8.4y)
Upper jaw	11%	<b>2%</b>	9%	32%
Lower jaw	48%	<b>1%</b>	44%	47%

Keski-Nisula K, Hernesniemi R, Heiskanen M, Keski-Nisula L, Varrela J. Orthodontic intervention in the early mixed dentition: A prospective, controlled study on the effects of the eruption guidance appliance. Am J Orthod Dentofacial Orthop 2008;133:254-260

# Research results – University of Turku, Finland



## Frequencies of malocclusions after treatment

	Treatment group	Control group
Overjet $\geq 5$ mm	0%	30%
Overbite $\geq 5$ mm	1%	38%
Open bite	1%	36%
Palatal contact	0%	40%
Crowding, maxilla	2%	32%
Crowding, mandible	1%	47%
Unilateral Class II	7%	17%
Bilateral Class II	3%	35%

Keski-Nisula K, Hernesniemi R, Heiskanen M, Keski-Nisula L, Varrela J. Orthodontic intervention in the early mixed dentition: A prospective, controlled study on the effects of the eruption guidance appliance. *Am J Orthod Dentofacial Orthop* 2008;133:254-260

# Research results – University of Turku, Finland



## Long term follow up shows stable treatment results

	Class II patients within the treatment group (n=50)		
	Start of active treatment (age: 5.1y)	End of active treatment (age: 8.4y)	Follow up (age: 16.7y)
Overjet	3.4	2.1	2.1
Overbite	3.4	2.2	3.1
Class I bilaterally	0%	78%	98%
ANB	5.9°	3.8°	2.0°



# Research results – University of Turku, Finland



## Long term follow up shows stable treatment results

		Class II patients within the treatment group (n=50)		
		Start of active treatment (age: 5.1y)	End of active treatment (age: 8.4y)	Follow up (age: 16.7y)
Mandibular length (Co-Gn)	Female	86.7 mm Burlington 6y: 94.1 mm	97.6 mm Burlington 9y: 103.3 mm	118.9 mm Burlington 18y: 118.9 mm
	Male	89.1 mm Burlington 6y: 96.6 mm	99.9 mm Burlington 9y: 105.0 mm	126.7 mm Burlington 18y: 127.2 mm

# Treatment Protocol – Research University of Turku, Finland



Start of active treatment:	When the first deciduous incisor exfoliates
Treatment:	The appliances were worn during sleeping hours only. If difficulties were encountered, daytime wear of 1 hour was recommended until the problems with night-wear disappeared.
End of active treatment:	After full eruption of all permanent incisors and first molars
Phase 2:	No second phase treatment.
Retention:	The same appliance was used for retention. Retention continued until all permanent canines, premolars, and second molars were fully erupted.

Keski-Nisula K; Keski-Nisula L; Salo H; Voipio K, Varrela J. Dentofacial Changes after Orthodontic Intervention with Eruption Guidance in the Early Mixed Dentition. Angle Orthod 2008;78:324-331  
Keski-Nisula K, Hernesniemi R, Heiskanen M, Keski-Nisula L, Varrela J. Orthodontic intervention in the early mixed dentition: A prospective, controlled study on the effects of the eruption guidance appliance. Am J Orthod Dentofacial Orthop 2008;133:254-260